

International Journal of
**Oral &
Maxillofacial
Surgery**

VOLUME 37 ISSUE 12 DECEMBER 2008 PAGES 1125-1132

ISSN: 0901-5027

www.ijoms.com

Reprint:

Comparison of chemically and pharmaceutically modified titanium and zirconia implant surfaces in dentistry: a study in sheep

J.D. Langhoff, K. Voelter, D. Scharnweber, M. Schnabelrauch, F. Schlottig, T. Hefti, K. Kalchofner, K. Nuss, B. von Rechenberg¹

CHURCHILL LIVINGSTONE 

Official Publication of
the International Association of
Oral and Maxillofacial Surgeons

REPRINTED BY



ELSEVIER

Contact: Adelina Campos

Tel: +44 (0) 207 424 4605

Fax: +44 (0) 207 424 4433

E-mail: a.campos@elsevier.com

<http://www.elsevierhealth.com/journals>

Research Paper
Dental Implants

Comparison of chemically and pharmaceutically modified titanium and zirconia implant surfaces in dentistry: a study in sheep

J. D. Langhoff^{1,*}, K. Voelter^{1,*},
D. Scharnweber²,
M. Schnabelrauch³, F. Schlottig⁴,
T. Hefti⁴, K. Kalchofner⁵, K. Nuss¹,
B. von Rechenberg¹

¹Musculoskeletal Research Unit, Equine Hospital, Vetsuisse Faculty ZH, University of Zurich, Winterthurerstr. 260, CH-8057 Zurich, Switzerland; ²Max Bergmann Center for Biomaterials, Institute of Materials Science, Dresden University of Technology, Budapester Str. 27, 01069 Dresden, Germany; ³Biomaterials Department, INNOVENT e. V., Pruessingstrasse 27B, D-07745 Jena, Germany; ⁴Thommen Medical, Hauptstrasse 26d, CH 4437 Waldenburg, Switzerland; ⁵Veterinary Anesthesiology, Equine Hospital, Vetsuisse Faculty ZH, University of Zurich, Winterthurerstr. 260, CH-8057 Zurich, Switzerland

J. D. Langhoff, K. Voelter, D. Scharnweber, M. Schnabelrauch, F. Schlottig, T. Hefti, K. Kalchofner, K. Nuss, B. von Rechenberg: Comparison of chemically and pharmaceutically modified titanium and zirconia implant surfaces in dentistry: a study in sheep. Int. J. Oral Maxillofac. Surg. 2008; 37: 1125–1132. © 2008 International Association of Oral and Maxillofacial Surgeons. Published by Elsevier Ltd. All rights reserved.

Abstract. Advanced surface modifications and materials were tested on the same implant geometry. Six types of dental implants were tested for osseointegration after 2, 4 and 8 weeks in a sheep pelvis model. Four titanium implant types were treated with newly developed surface modifications, of which two were chemically and two were pharmacologically modified. One implant was made of zirconia. A sandblasted and acid-etched titanium surface was used as reference. The chemically modified implants were plasma-anodized or coated with calcium phosphate. The pharmacological coatings contained either bisphosphonate or collagen type I with chondroitin sulphate. The implants were evaluated using macroscopic, radiographic and histomorphometric methods.

All implants were well osseointegrated at the time of death. All titanium implants had similar bone implant contact (BIC) at 2 weeks (57–61%); only zirconia was better (77%). The main BIC increase was between 2 and 4 weeks. The pharmacologically coated implants (78–79%) and the calcium phosphate coating (83%) showed similar results compared with the reference implant (80%) at 8 weeks. There were no significant differences in BIC. Compared with previous studies the results of all implants were comparatively good.

Keywords: dental implants; zirconia; titanium; surface modification; histomorphometry; sheep.

Accepted for publication 3 September 2008
Available online 31 October 2008

Over the last decades, titanium or its alloys has become a gold standard as a base for tooth reconstruction in dental implantology, because of its mechanical strength, chemical stability and excellent biocom-

patibility²². These properties ensure good anchorage within the mandible or maxillary bone. The aim is to achieve shorter healing periods for implants, in order to load them as soon as possible after sur-

gery, while allowing efficient osseointegration. Apart from good implant design

* The first two authors contributed equally to this work.

related to mechanical anchorage, these requirements may be met by modifying the implant surface, bearing in mind that the most important surface properties for (metallic) implants are topography, chemistry, surface charge and wettability⁵.

To improve surface properties two main approaches were used either optimizing the micro-roughness (e.g. sandblasting and acid-etching) or applying bioactive coatings (e.g. calcium phosphate, bisphosphonate, collagen). Optimizing the micro-roughness results in enlarged surfaces providing improved conditions for osteogenic cell attachment and proliferation. In recent studies, histomorphometric and biomechanical comparisons of such optimized implant surfaces to machined implants showed better values for short time osseointegration⁶. These surfaces were also optimized for their wettability for potentially enhanced implant-tissue interaction and better osseointegration, achieved by rinsing under an N₂ atmosphere and submersion in an isotonic NaCl solution following acid-etching⁷. The new generation of thin calcium phosphate based coatings provide high wettability and were described as highly potential²⁴.

Another approach is to add bioactive components to titanium surfaces. One method uses extracellular matrix ligands, the RGD-peptide sequence, for better osteoblast attachment and enhanced bone remodelling¹⁸. SCHULER et al.¹⁹ used a functionalized coating (poly(L-lysine)-graft-poly(ethylene glycol)) to present bioligands for interaction with osteoblasts *in vitro*. Faster colonization of the implant surface by osteoblasts also inhibits bacterial growth.

A new method uses nucleic acid, single strands, fixed electrochemically via their termini by anodically growing an oxide layer on Ti6Al7Nb as anchor structures to load surfaces with bioactive molecules linked to complementary strands¹².

The bioactivity of surfaces can be enhanced using drug eluting coatings, which are supposed to influence bone healing, for example by activating osteoblasts, suppressing osteoclasts or stimulating the production and distribution of growth factors such as BMP-2.

An increase in the mechanical fixation of implants has been achieved with local delivery of bisphosphonates¹⁵. Other studies showed the high potential of growth factors such as BMP-2⁸.

Zirconia has gained attention as an implant material because of its white colour, which makes it aesthetically attractive¹⁴. Apical bone loss and gingival

degeneration associated with implants often uncover parts of the metal implant showing a bluish discoloration of the overlying gingiva. The use of zirconia implants avoids this complication and accedes to the request of many patients for metal-free implants. The material also provides high strength, fracture toughness and biocompatibility¹⁶. Osseointegration is approximately the same as with titanium⁹.

The authors hypothesize that chemical and pharmacological surface modifications to titanium initiate a stronger bone response than an advanced sandblasted and acid-etched surface alone. They tested whether a surface-treated zirconia can compete with sophisticated titanium surfaces. The bone response to the implant modifications was tested on the identical established implant geometry using histomorphometry.

Material and methods

Dental implants

Overall, 6 types of implants with identical implant geometry were tested (Table 1). All titanium and zirconia implants were sandblasted and partially etched prior to the surface treatments, similar to the reference. The surfaces of the chemically modified implants were either plasma anodized or coated with calcium phosphate. The pharmacologically modified implants were either coated with bisphosphonate or collagen type I. An acid-etched and sandblasted implant made of titanium (grade 4, SPI[®]ELEMENT, Thommen Medical AG, Waldenburg, Switzerland) served as the reference and control for the surface modifications.

Surface details

The calcium phosphate surface was coated using electrochemical assistance in an aqueous solution containing calcium and phosphate ions. The coating consists of the two calcium phosphate phases, hydroxyapatite and brushite, and is commercially available. The anodic plasma chemical surface modification method is an advanced anodization method, which allows anodic oxide layer formation and incorporation of calcium phosphate phases in a single process step. The method exploits the dielectric breakdown of anodic oxide films to produce a porous oxide layer that contains significant amounts of electrolyte components. The electrolyte contained calcium and phosphate ions, leading to a porous surface containing calcium phosphate.

The collagen coating was based on an extracellular matrix containing chondroitin sulphate, prepared by fibrillogenesis of the collagen in the presence of CS, and performed as dip coating in a collagen/chondroitin sulphate solution. The bisphosphonate coated implants were immobilized with an alendronate solution, to a final concentration of 10 µg/cm².

The zirconia implants were manufactured from yttrium partially stabilized zirconia, medical grade. The zirconia implants were sandblasted and etched in an alkaline bath.

Animal model and study design

A total of 15 sheep underwent surgery. All sheep were full-grown, aged 2–3 years, not gestating females and 49–87 kg (average 68 kg). General guidelines for care

Table 1. Implant groups, their abbreviations and sample size.

	Implant type	Abbreviation	Weeks	Sample size
Chemical	Sandblasted and acid etched*	Ref	2	9
			4	6
			8	6
	Calcium Phosphate	CaP	2	6
			4	6
			8	6
	Plasma Anodized	APC	2	6
			4	6
			8	6
Pharmacological	Collagen I + Chondroitin Sulfate	Coll+	2	6
			4	6
			8	6
	Bisphosphonate	BisP	2	6
			4	6
			8	6
Chemical	Zirconia	Zr	2	6
			4	6
			8	6

* SPI ELEMENT, Thommen Medical.

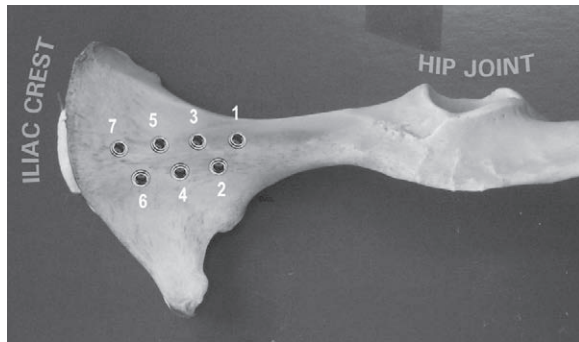


Fig. 1. Implant locations in the iliac bone of a sheep in a dorso-ventral view.

and use of animals in research have been followed and all experiments were approved by the local veterinary authorities (approval no.159/2005). The sheep were kept in groups containing a maximum of 4 animals. Their general condition was checked three times a day to accomplish pain monitoring, to detect variations in wellbeing and injuries of the musculoskeletal system. All implants (total $n = 110$) were placed in the iliac bones of the pelvis. Bone structure was predominantly of cancellous quality in the cranial part with increasing cortical thickness (up to 3 mm) toward the caudal part. An implantation scheme was worked out to distribute all implant types homogeneously to 7 implantation sites per iliac bone (Fig. 1). The study design aimed to achieve the statistical minimum of 6 samples per implant group (one implant type was not evaluated for the present study) for each healing period of 2, 4 and 8 weeks, with 5 animals per time point. Additional implants were placed for a concurrent biomechanical analysis (the topic of a separate study). Animals were killed in the University's slaughterhouse according to ethical standards.

Animal surgery

After sedation with medetomidine (5 µg/kg, Domitor™, Orion Pharma Animal Health, Finland) anaesthesia was induced using ketamine (2 mg/kg, Narketan® 10, Chassot GmbH, Germany) in combination with diazepam (0.01 mg/kg, Valium®, Roche, Switzerland). After intubation anaesthesia was maintained with 0.8 Vol% isoflurane (Forene®, Abbot AG, Switzerland) in O₂ and an infusion of Ringer's solution with 60 mg/l ketamine (Narketan™ 10, Chassot GmbH, Germany) at a rate of 10 ml/kg/h. As a prophylaxis against infection all animals received 30,000 IU/kg penicillin (Hoechst AG, Germany) and 6 mg/kg gentamicin (Streuli & Co AG, Switzerland) intrave-

nously three times a day. In addition, they received 500 Units of equine tetanus serum as a single subcutaneous application (Tetanus Serum Veterinaria AG, Zurich, Switzerland).

The animals were placed in lateral recumbency and access to the pelvis was achieved using a standard operation procedure. A 20 cm long cut was made in the skin in the longitudinal direction of the iliac bone at the mid-pelvis line. The fascia was cut and the middle gluteal muscle and tensor fasciae latae were separated by blunt dissection. In the distal half of the iliac bone the tendinous insertion of the deep and middle gluteal muscles was severed from the iliac crest with a scalpel and the muscles were bluntly removed from the iliac bone shaft. A Finocchio retractor was used to expose the entire iliac wing. Holes were drilled using the SPI® VECTODrill™-System (Thommen Medical AG, Waldenburg, Switzerland) with a 2.0 mm pilot drill, widened with a 2.8 mm and finally with a 3.5 mm drill. A drill sleeve was used to ensure the designated drill depth according to the implant design and the depth was confirmed with a depth gauge (Thommen Medical AG, Waldenburg, Switzerland). The self-tapping implants (SPI® ELEMENT, Thommen Medical AG, Waldenburg, Switzerland) were placed according to the implantation scheme and using the specific instruments supplied with the implant system. Healing caps were placed to prevent tissue ingrowth in the abutment connection area of the implant head. Implant setting was documented with digital photographs. The muscles were repositioned and the tendinous insertion resutured to its origin using a cross pattern of single (at the edges) and continuous sutures. Fascia and subcutis were closed with the same synthetic resorbable suture (Polyglactin; Vicryl® 2-0, Johnson & Johnson Intl.) while the skin was closed with staples (Davis + Geck Appose ULC®). Gauze was applied as protection

for the wound before the animal was turned over to the other side. The contralateral pelvis was operated on in an identical manner.

Postoperative treatment consisted of an antiphlogistic and analgesic, as well as antibiotic medication for 4 days (buprenorphin 0.01 mg/kg i.m. t.i.d. during the first 24 h, benzylpenicillin (30000 I.U./kg i.v. b.i.d.), gentamicin (4 mg/kg i.v. s.i.d.) and carprofen (4 mg/kg i.v. s.i.d.).

Fluorochrome labelling

Bone healing and remodelling was followed by labelling new bone apposition with fluorochrome dyes¹⁷ at defined points of time. The first labelling with calcein green (10 mg/kg s.c.) was performed 2 weeks after implantation. In the 8 week-group, a second label was injected at 6 weeks using xylenol orange (90 mg/kg s.c.).

Preparation and evaluation of bone samples

The bones were harvested after killing the animals. They were freed of all soft tissue, revealing the implants in the iliac bone. The firm seat of the implants within the bone was tested qualitatively by manual pressure and the caps were removed. Thereafter, the intact pelvis bone was radiographed using a faxitron machine (Cabinet X-ray-faxitron series, model 43855A, Hewlett Packard®, USA) for documentation of implant placement and verification of proper seat. Then the bone was cut into 1.5 × 1.5 cm cubes with a band saw (K 410, Kolbe GmbH, Elchingen, Germany), containing one implant. Samples were fixed in 40% alcoholic solution for 14 days and were routinely processed for non-decalcified bone histology¹¹. They were submitted to a dehydration process in an ascending series of ethanol solutions (50, 70, 96, 100%), before degreasing in xylene under vacuum. Samples were infiltrated in pMMA solution (poly methacrylic acid-methylester; dibutylphthalate and perka-dox in a proportion 89.5: 10: 0.5) for 7 days, embedded and polymerized in Teflon containers. Samples were positioned to assure that implants were cut parallel to the longitudinal axis. Two ground sections were cut at the maximum diameter of the implant using a low speed diamond saw (Leica® SP 1600, Leica® Instruments GmbH, Nussloch, Germany). One section of 200 µm was used for normal bone histology, applying a surface staining with toluidine blue. The thinner,

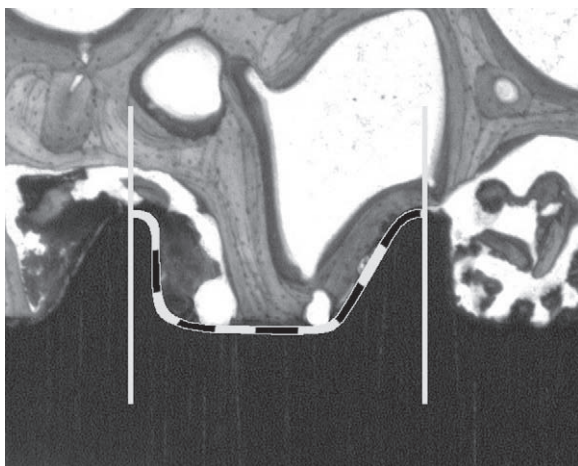


Fig. 2. Illustration of the thread wise evaluation of the bone implant contact (BIC). Estimation of the percentage was supported with a 10% step grid.

native section (150 μm) was used for fluorescence microscopy (Leica, DMR, UV light source and Filter I3 for calcein green and xylenol orange, Glattbrugg, Switzerland). Before the 200 μm sections were glued to the opal, acrylic Plexiglas slides (Wachendorf, Perspex GS, Acrylic-glas Opal 1013) microradiographs, using a high-resolution analogue film (Kodak Oncology Film, Eastman Kodak Company, Rochester, NY), were taken to visualize the stage of calcification of the bone samples adjacent to the metallic implants.

Evaluation

Using the toluidine-stained thick sections, a semi-quantitative evaluation of the bone implant contact (BIC) was made. For this, the percentage of direct contact between mineralized bone and the titanium surface was determined by intersection counting within the thread area. Six thread pitches were counted per sample. The evaluation was performed at calibrated digital pictures at 10x magnification (Leica microscope M420, Leica DFC320, 3088x2550 pixels, Leica Microsystems, Germany). Two pictures covered the full threaded part in high resolution. The percentage of BIC was estimated in steps of 10% (Fig. 2). Means of thread counts per implant were calculated.

Statistical analysis

In a first step, factors as individual difference and position of the implant could be excluded as not significant. In a second step, comparison of implant types at each point of time was performed. The analysis of variance (ANOVA) was used to iden-

tify significant differences, mean values and standard deviations using a specific soft ware (SPSS 13.0 for Macintosh). Significance level was set at $p < 0.05$.

Results

Surgery and postoperative period

All surgery was uneventful and the animals recovered from anaesthesia quickly. The sheep were able to walk immediately after recovery, but showed signs of mild muscle soreness for 1–2 days after surgery. Thereafter, no signs of lameness or other discomfort were seen. Insertion of all implants proceeded smoothly, but dur-

ing implantation it was noticed, that the zirconia implants required slightly more force for insertion compared with the titanium implants.

Macroscopic and radiological evaluation

After preparation of the muscle above the implants, the tissue layer directly at the bone–implant surface was gel- and fat-like after 2 weeks. A soft tissue layer had formed after 4 weeks, which developed into a periosteum-like layer with callus formation later. At 2 and 4 weeks, haematoma were rarely visible around the implants. Overall, no signs of inflammation or infection could be found, indicated through swelling, reddening or other degradation of surrounding tissue. All implants were firmly seated.

Radiographs demonstrated all implants to be still in place. No fractures or zones of bone resorption could be found.

Microradiographic evaluation

Radiographs of the thick sections confirmed the macroradiographic results of absence of bone resorption. Radiodense structures were visible in detail and could be clearly identified as bone (Fig. 3). Radiodense structures and bone tissue stained with toluidine blue matched exactly. Except for a small seam of osteoid all of the new bone formation was calcified at all time points. The microradiographs were not evaluated additionally besides the stained histologies.

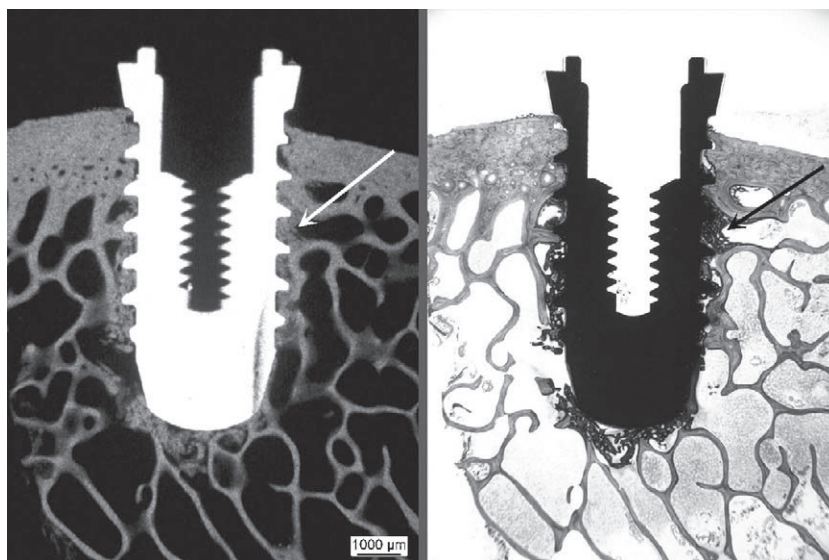


Fig. 3. Calcification of new bone formation (arrows) at the implant was proved by matching areas of radiodense (microradiograph, on the left) and stained structures (toluidine blue dye, on the right) in histological thick sections. Overview picture (5.8x) of a bisphosphonate-coated titanium implant at 4 weeks.

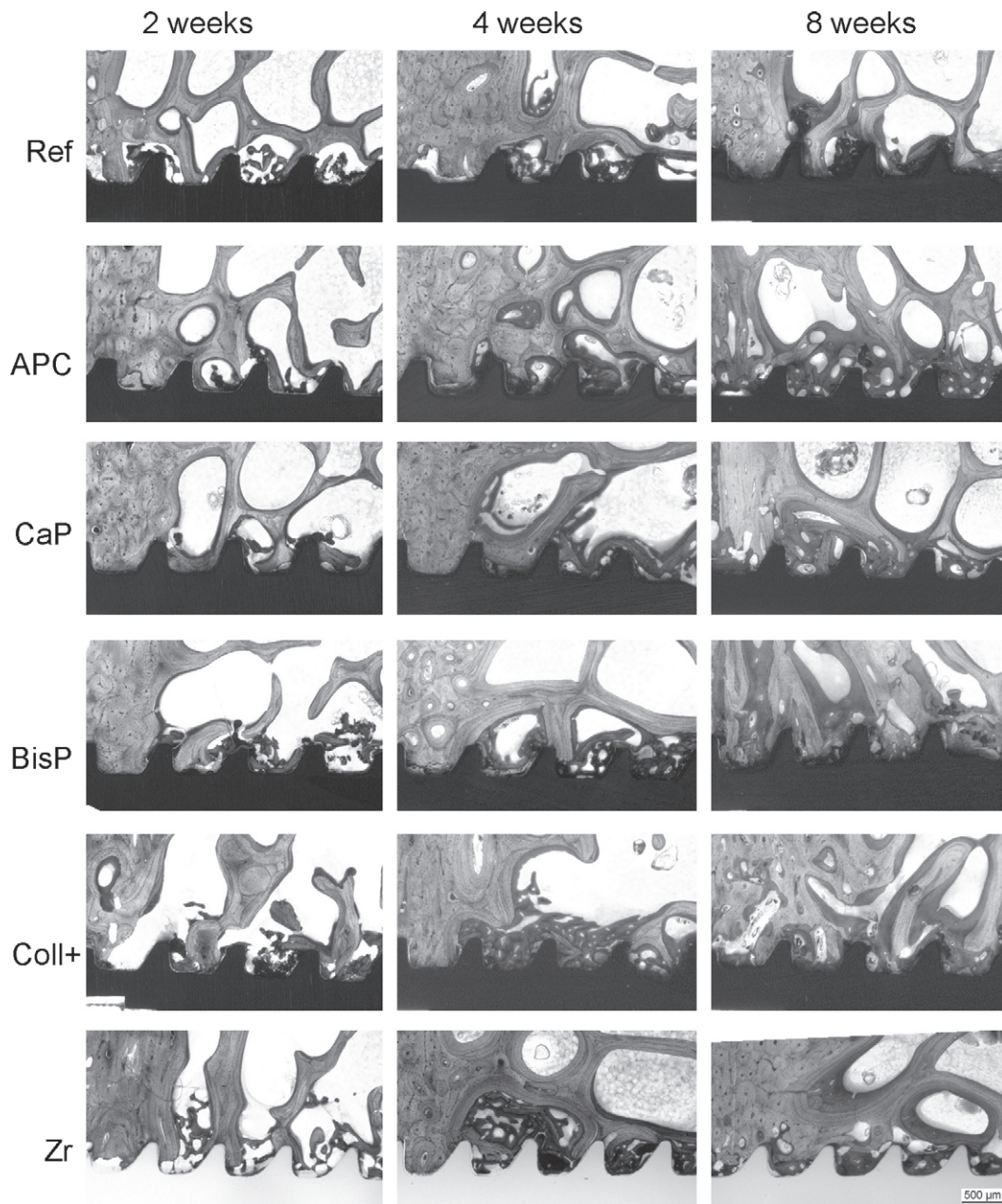


Fig. 4. A matrix of representative histological pictures of all implant types and time points (2, 4 and 8 weeks) at 10 \times magnification. Surface were either sandblasted and acid etched (Ref), anodic plasma treated (APC), calcium phosphate (CaP), bisphosphonate (BisP), collagen with chondroitin sulfate (Coll+) coated or of zirconia (Zr).

Evaluation of histology samples

All sections were cut precisely in the middle axis, capturing the entire implant, enabling standardized evaluation.

Qualitative microscopic evaluation revealed that implants were generally well seated within the bone. New bone formation, visible as dark-bluish stain, was present around all implants in the cancellous bone by 2 weeks and built up steadily until 8 weeks (Fig. 4). Bony debris was found in the remaining cavity of the implant tip, where new bone was found by 2 weeks.

Remodeling in the cortical bone started by 4 weeks in some samples and was prominent at all implant sites at 8 weeks. There were no signs of pathological bone resorption indicative of excessive mechanical instability or issues of bioincompatibility (accumulation of inflammatory cells) in any implant. Striking differences between the implant types were not observed in the qualitative evaluation.

Evaluation of BIC

Results of the BIC measurements (Fig. 5) demonstrated clear trends between surface

types and time points. All titanium types were nearly similar at 2 weeks (59–62% BIC) and increased with time (78–83%), except the plasma anodized surface (58%).

The two chemical surface modifications performed very differently. The calcium phosphate surface showed similar values, with the main increase at 2–4 weeks, like the reference, and a slight increase towards week 8. In contrast, the plasma anodized surface lost 2% bone contact initially and did not improve after 4 weeks.

Pharmacologically modified surfaces performed close to the reference. The

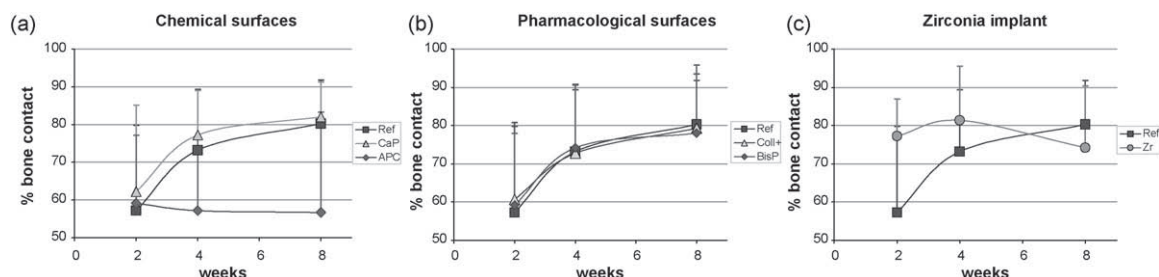


Fig. 5. Results of the bone-implant contact (BIC) measurements are given according to the three groups of implant types: Chemical (a) and pharmacological (b) titanium surface modifications and a zirconia implant (c) were evaluated for bone response and referenced by a sandblasted and acid etched implant (SPI[®]ELEMENT). Significant differences were not found between the groups of 6 samples per implant and time point.

collagen with chondroitin sulphate surface showed slightly higher values than the reference implant at 2 weeks and continued nearly equally, whereas the bisphosphonate coated surface was higher at 2 and 4 weeks.

The zirconia implant presented 20% more bone contact than the titanium implants at 2 weeks, improved toward 4 weeks, then reduced at 8 weeks to below the level of the reference surface.

The overall performance of the new surfaces, except the plasma anodized, was better than the reference. Statistically significant differences for BIC were not found.

Evaluation of fluorochrome labeling

At 4 weeks, calcein green fluorescent dye was exclusively visible in the new bone directly at the implant, while in the 8 week sections xylenol orange was found directly at the implant surface. In those specimens calcein green was found at a greater distance from the implant surface. Differences in signals or deposition of fluorochrome dyes could not be found between the implant types and, therefore, further histomorphometrical evaluations were not performed.

Discussion

In this study the osseointegration of market standard dental implants (titanium grade 4, sandblasted, acid etched) was compared with surface-treated implants that were either chemically (plasma anodized, calcium phosphate coated) or pharmacologically modified (bisphosphonate, collagen type 1 containing chondroitin sulphate) or to zirconia implants. An experimental sheep pelvis model was used, where all implants showed good biocompatibility and osseointegration. Although statistically not significant, there was a clear tendency for the chemically and pharmacologically modified implants

to show better BIC values at 8 weeks compared to the anodic plasma treated surface or zirconia implants.

Finding an appropriate animal model for testing dental implants is difficult, mainly because the morphology of teeth in animals is different from that of humans. Pigs and dogs are commonly used as experimental animals, if dental implants are applied intra-orally¹. Apart from different root systems and the form of the incisor and molar teeth, mouth hygiene is a problem in those animals after setting dental implants and, thus, healing without infection may pose a problem.

Osseointegration is often tested in other locations, such as the femoral condyle¹³. Even though the risk of infection may be excluded, the cancellous bone of the femoral condyle is more compact and stronger compared to the mandible. The authors' group has developed an animal model in the iliac shaft of sheep, where the structure of the bone is similar to that of the human mandible, as described by the Lekholm and Zarb index¹⁰. Sheep is a well-established animal for orthopedic research, because of the similar remodeling rate, bone structure and bone proportions as humans³. The pelvis model allows the implantation of a relatively high number of implants in one sheep; by operating on both sides intra- and inter-individual comparisons can be made. The animal model serves well from an ethical standpoint considering animal welfare and protection, because surgery does not interfere significantly with normal ambulation of the sheep, housing can be easily provided appropriate to the species and handling does not cause excessive stress.

The study design achieved the statistical minimum within the limitations of a justifiable use of animals. The implantation scheme reduced the influences of the individual and the implantation site using a rotation system of sample distribution. The iliac bone as implantation site could

be established as a standard with a zero failure rate of operation and implantation. Standard dental equipment (SPI[®]-System, Thommen Medical) could be used without limitations for predrilling and implant placement. In this manner, clinical standard procedures and precision could be applied. Also sample preparation for histology did not involve complications or loss of samples. The sample preparation proved to be a very effective and reliable method for longitudinal sections. All sections were cut in the centre of the implants with very little variation, so histological evaluation of osseointegration could be well standardized. The present study was mainly focused on the morphological aspects of osseointegration, as the histological picture did not show any abnormalities on the cellular level. As a common tool in dental research, BIC was regarded as an appropriate method to measure the performance of an implant²³. The estimation of bone contact in 10% steps per screw thread was regarded as adequate. Calculation of means for each implant was close to the accuracy of a quantitative method, since the full threaded part of the implant was evaluated.

Although good standardization of surgery and sample preparation procedures could be achieved, differences between groups did not reach statistical significance. The two main reasons for this were the relatively small sample size and the good material properties of all the tested implants. The minimal sample size for statistical evaluation was chosen considering animal welfare issues and ethical concerns related to the use of animals in experimental research. Since the sandblasted and acid-etched implants (Thommen Medical SPI[®]-System) used as a reference show good performance owing to their original titanium properties⁶, differences to the modified implants were expected to be relatively small. Tendencies for improved osseointegration follow-

ing implant modification were clearly shown and allow further research and testing to be focused on the implants showing superior performance.

The improved values of the pharmacologically modified surfaces may be attributed to the enhanced adhesion of osteoblasts and the suppression of osteoclasts, or a combination of both. The early attachment of the old bone to the implant, including the inhibition of function of osteoclasts (bisphosphonates) can hamper resorption and lead to a better anchorage at the very early stage of bone healing²⁰. The reduction of micromotion at a very early stage after implantation is therefore considered responsible for good osseointegration of bisphosphonate-coated implants, since initially mainly bone formation occurs. Resorption of the old bone matrix may take place later when the bisphosphonates are resorbed and the implant has gained a certain stability²⁵. This difference was not confirmed for BIC in this study.

Collagen containing chondroitin sulphate surfaces increased cell proliferation and activated osteoblasts in cell cultures as demonstrated through higher values of bone markers (osteopontin, alkaline phosphatase) and larger cell size⁴. Adhesion molecules such as vinculin, actin and integrins were up-regulated *in vitro*. Inhibition of osteoclasts does not occur in parallel. Recruitment and activation of osteoclasts and subsequent bone resorption at the surface of the bone lesion is not inhibited and takes its normal course. As bone resorption normally precedes new bone formation and deposition, it may result in temporary microinstability at the bone-implant interface and thus, less stability of implants in the immediate and early postoperative phase²¹.

Cell proliferation, cell size and regulation of adhesion molecules were not investigated in the current study, where osseointegration was assessed using the histology of non-decalcified bone samples containing the implants alone. Although it would be interesting to understand the exact mechanism of osseointegration on a molecular level, it would not change the practical and clinical results, where histology demonstrated a sound performance for bisphosphonate-coated implants.

Zirconia implants showed good osseointegration in histology. The additional etching process and the roughness achieved was good for cell attachment and bone apposition and seemed to make a difference in the early postoperative phase at 2 and 4 weeks. Later the BIC values were lower compared with the chemically

or pharmacologically treated implants and the reference titanium implants. Whether this is due to the surface of the implant is unknown and will be investigated.

Calcium phosphate coated implants showed similar BIC rates as the pharmacologically treated surfaces, with a BIC rate of approximately 80% after 8 weeks, comparable with those of other advanced bioactive surfaces^{2,5}.

In conclusion, the hypothesis of improved surfaces could not be accepted even though there were trends for better performance for some surface modifications. All tested implant types demonstrated good biocompatibility and osseointegration, with only small differences compared with the reference implant surface.

Further studies will refine the concentration of bioactive substances used in this study and explain the reactions on a cellular level as well as prove those concepts in clinical conditions.

Acknowledgements. Implants were provided by Thommen Medical AG, Waldenburg, Switzerland. The excellent work by S. Bierbaum (Biomaterials Department, INNOVENT e. V) for providing the collagen containing chondroitin sulfate coating, by V.M.Frauchiger (Dr Robert Mathys Foundation, Bischmattstrasse 12, 2544 Bettlach, Switzerland) for providing the plasma anodized coating, by A.Kautz (Biomaterials Department, INNOVENT e. V) for providing the bisphosphonate coating and P.Zeggel (DOT GmbH, Charles-Darwin-Ring 1a, 18059 Rostock, Germany) for providing the calcium phosphate coating is highly appreciated.

References

1. ABRAHAMSSON I, ZITZMANN NU, BERGLUNDH T, WENNERBERG A, LINDHE J. Bone and soft tissue integration to titanium implants with different surface topography: an experimental study in the dog. *Int J Oral Maxillofac Implants* 2001; **16**: 323–332.
2. ALBREKTSSON T, WENNERBERG A. Oral implant surfaces: Part 1—review focusing on topographic and chemical properties of different surfaces and *in vivo* responses to them. *Int J Prosthodont* 2004; **17**: 536–543.
3. AUER JA, GOODSHIP A, ARNOCKY S, PEARCE S, PRICE J, CLAES L, VON RECHENBERG B, HOFMANN-AMTENBRINCK M, SCHNEIDER E, MULLER-TERPITZ R, THIELE F, RIPPE KP, GRAINGER DW. Refining animal models in fracture research: seeking consensus in optimising both animal welfare and scientific validity

- for appropriate biomedical use. *BMC Musculoskelet Disord* 2007; **8**: 72.
4. BIERBAUM S, DOUGLAS T, HANKE T, SCHARNWEBER D, TIPPELT S, MONSEES TK, FUNK RH, WORCH H. Collagenous matrix coatings on titanium implants modified with decorin and chondroitin sulfate: characterization and influence on osteoblastic cells. *J Biomed Mater Res A* 2006; **77**: 551–562.
5. BUSER D, BROGGINI N, WIELAND M, SCHENK RK, DENZER AJ, COCHRAN DL, HOFFMANN B, LUSSI A, STEINMANN SG. Enhanced bone apposition to a chemically modified SLA titanium surface. *J Dent Res* 2004; **83**: 529–533.
6. BUSER D, NYDEGGER T, HIRT HP, COCHRAN DL, NOLTE LP. Removal torque values of titanium implants in the maxilla of miniature pigs. *Int J Oral Maxillofac Implants* 1998; **13**: 611–619.
7. FERGUSON SJ, BROGGINI N, WIELAND M, DE WILD M, RUPP F, GEIS-GERSTORFER J, COCHRAN DL, BUSER D. Biomechanical evaluation of the interfacial strength of a chemically modified sandblasted and acid-etched titanium surface. *J Biomed Mater Res A* 2006; **78**: 291–297.
8. JONES AA, BUSER D, SCHENK R, WOZNEY J, COCHRAN DL. The effect of rhBMP-2 around endosseous implants with and without membranes in the canine model. *J Periodontol* 2006; **77**: 1184–1193.
9. KOHAL RJ, WENG D, BACHLE M, STRUB JR. Loaded custom-made zirconia and titanium implants show similar osseointegration: an animal experiment. *J Periodontol* 2004; **75**: 1262–1268.
10. LEKHOLM U, ZARB G. Patient selection and preparation. Chicago Quintessence Publishing Co 1985: pp. 199–209.
11. LEUTENEGGER CM, VON RECHENBERG B, HUDER JB, ZLINSKY K, MISLIN C, AKENS MK, AUER J, LUTZ H. Quantitative real-time PCR for equine cytokine mRNA in nondecalcified bone tissue embedded in methyl methacrylate. *Calcif Tissue Int* 1999; **65**: 378–383.
12. MICHAEL J, BEUTNER R, HEMPEL U, SCHARNWEBER D, WORCH H, SCHWENZER B. Surface modification of titanium-based alloys with bioactive molecules using electrochemically fixed nucleic acids. *J Biomed Mater Res B Appl Biomater* 2007; **80**: 146–155.
13. NUSS KM, AUER JA, BOOS A, VON RECHENBERG B. An animal model in sheep for biocompatibility testing of biomaterials in cancellous bones. *BMC Musculoskelet Disord* 2006; **7**: 67.
14. OLIVA J, OLIVA X, OLIVA JD. One-year follow-up of first consecutive 100 zirconia dental implants in humans: a comparison of two different rough surfaces. *Int J Oral Maxillofac Implants* 2007; **22**: 430–435.
15. PETER B, GAUTHIER O, LAIB S, BUJOLI B, GUICHEUX J, JANVIER P, VAN LENTHE GH, MULLER R, ZAMBELLI PY, BOULER

- JM, PIOLETTI DP. Local delivery of bisphosphonate from coated orthopedic implants increases implants mechanical stability in osteoporotic rats. *J Biomed Mater Res A* 2006; **76**: 133–143.
16. PICONI C, MACCAURO G. Zirconia as a ceramic biomaterial. *Biomaterials* 1999; **20**: 1–25.
17. RAHN BV, BACELLAR FC, TRAPP L, PERREN SM. A method for morphometry of bone formation using fluorochromes. *Aktuelle Traumatol* 1980; **10**: 109–115.
18. RAMMELT S, ILLERT T, BIERBAUM S, SCHARNWEBER D, ZWIPP H, SCHNEIDERS W. Coating of titanium implants with collagen. RGD peptide and chondroitin sulfate. *Biomaterials* 2006; **27**: 5561–5571.
19. SCHULER M, OWEN GR, HAMILTON DW, DE WILD M, TEXTOR M, BRUNETTE DM, TOSATTI SG. Biomimetic modification of titanium dental implant model surfaces using the RGDSP-peptide sequence: a cell morphology study. *Biomaterials* 2006; **27**: 4003–4015.
20. SHIBUTANI T, INUDUKA A, HORIKI I, LUAN Q, IWAYAMA Y. Bisphosphonate inhibits alveolar bone resorption in experimentally-induced peri-implantitis in dogs. *Clin Oral Implants Res* 2001; **12**: 109–114.
21. STADLINGER B, PILLING E, MAI R, BIERBAUM S, BERHARDT R, SCHARNWEBER D, ECKELT U. Effect of biological implant surface coatings on bone formation, applying collagen, proteoglycans, glycosaminoglycans and growth factors. *J Mater Sci Mater Med* 2008; **19**: 1043–1049.
22. STEINEMANN SG. Titanium—the material of choice? *Periodontol* 2000 1998; **17**: 7–21.
23. SUL YT, JOHANSSON CB, JEONG Y, ROSER K, WENNERBERG A, ALBREKTSSON T. Oxidized implants and their influence on the bone response. *J Mater Sci Mater Med* 2001; **12**: 1025–1031.
24. SZMUKLER-MONCLER S, ZEGGEL P, PERLIN D, BERNARD JP, NEUMANN HG. From Microroughness to Resorbable Bioactive Coatings. In: ELLINGSEN JE, LYGSTADAAS SP, eds: *Bio-Implant Interface*. CRC Press 2003: 73–100.
25. TANZER M, KARABASZ D, KRYGIER JJ, COHEN R, BOBYN JD. The Otto Aufranc Award: bone augmentation around and within porous implants by local bisphosphonate elution. *Clin Orthop Relat Res* 2005; **441**: 30–39.

Address:
Jens D. Langhoff
Musculoskeletal Research Unit
Equine Hospital
Vetsuisse Faculty ZH
University of Zurich
Winterthurerstr. 260
8057 Zurich
Switzerland
Tel: +41 76 432 27 38
Fax: +41 44 635 8905
E-mail: vetclinics@langhoff.ch